

3M™ Filtek™ One Bulk Fill Restorative

Treatment of a deep carious lesion of second lower premolar with 3M™ Filtek™ One Bulk Fill Restorative.

Clinical dentistry and photography by: Dr. Filippo Dini, Viareggio, Italy

3M Science.
Applied to Life.™

Treatment of a deep carious lesion of second lower premolar with 3M™ Filtek™ One Bulk Fill Restorative

Clinical dentistry and photography by: Dr. Filippo Dini, Viareggio, Italy

About the Case:

Male patient 47 years old.

Patient reported pain when drinking cold beverages.
The x-ray showed the extension of caries close to pulp.
Endodontic treatment was required.

Challenge:

The deep cervical margin and the preservation of tissue for the post-endo restoration posed challenges in this case. Excellent adaptation between the material and cavity walls is critical.

CLINICAL CASE

Step-by-Step:

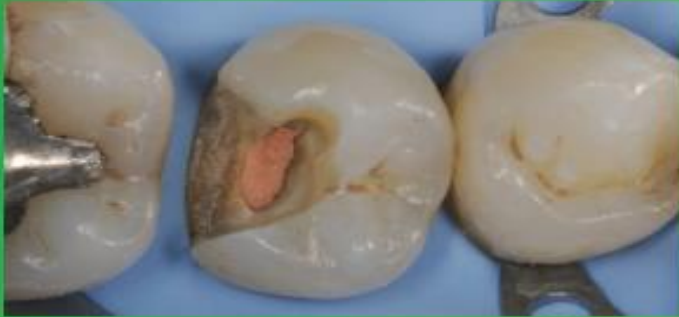

Fig. 1: Initial Situation: Second lower right premolar with a deep carious lesion restoration that required endodontic treatment. Image is showing the final preparation after removing the temporary filling.

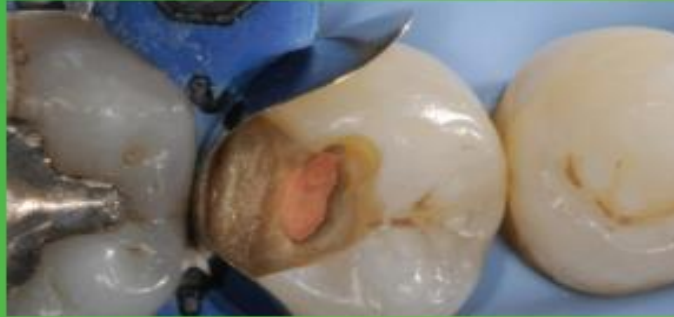


Fig. 2: Placement and adaptation of the sectional matrix.

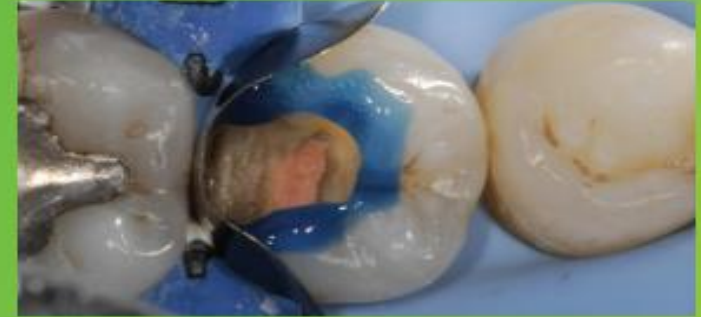

Fig. 3: Enamel is etched for 15 seconds using 3M™ Scotchbond™ Universal Etchant for a selective etch approach, followed by rinsing and drying.

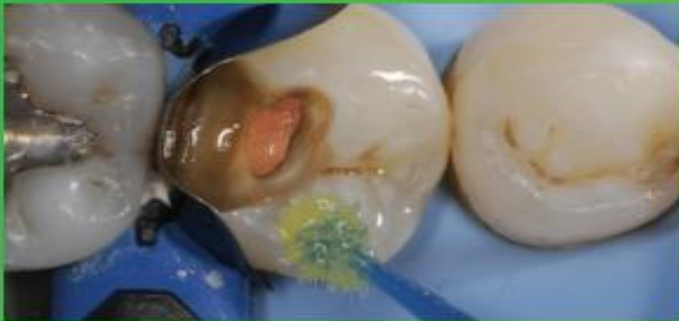

Fig. 4: 3M™ Scotchbond™ Universal Adhesive is applied and scrubbed into the surface for 20 seconds.

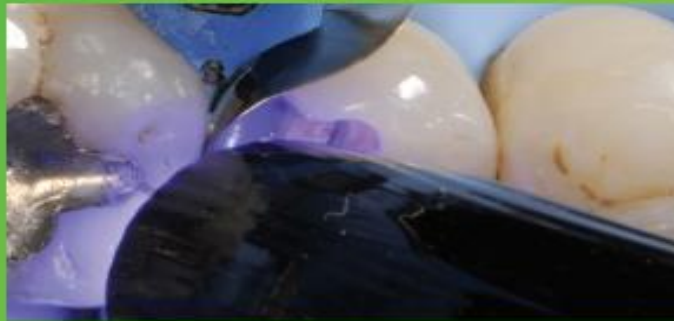

Fig. 5: After air drying for approximately 5 seconds, the adhesive is light cured for 10 seconds with 3M™ Elipar™ DeepCure-S LED Curing Light.

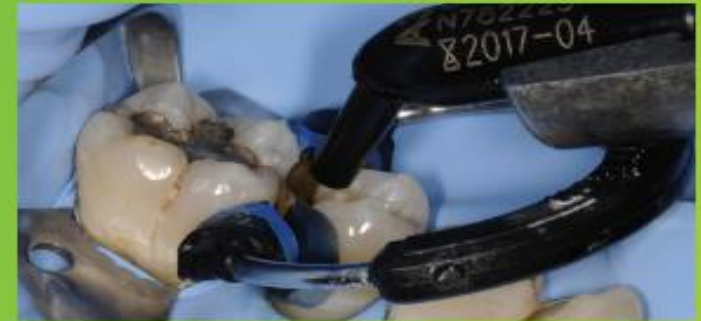

Fig. 6: 3M™ Filtek™ One Bulk Fill Restorative, in shade A3, is directly placed into the cavity in a single increment and then cured according to the Instructions for Use.

Treatment of a deep carious lesion of second lower premolar with 3M™ Filtek™ One Bulk Fill Restorative (continued)

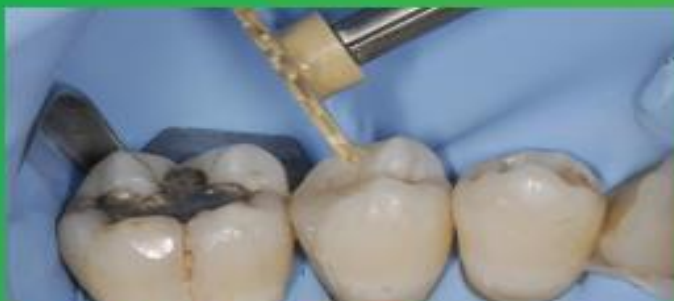

Fig. 7: Following finishing, to achieve the final polish of the restoration, the 3M™ Sof-Lex™ Pre-Polishing Spiral is used, as a first step, on a moist surface.

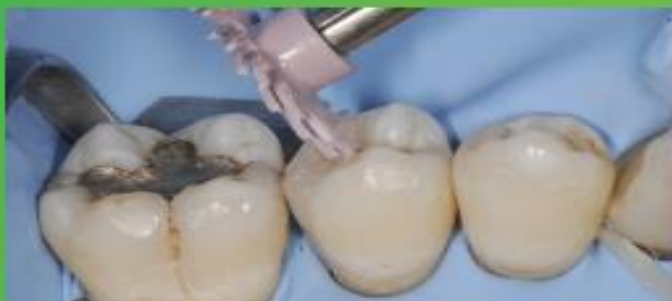

Fig. 8: A final high-gloss polish is created using the 3M™ Sof-Lex™ Diamond Polishing Spiral on a moist surface.

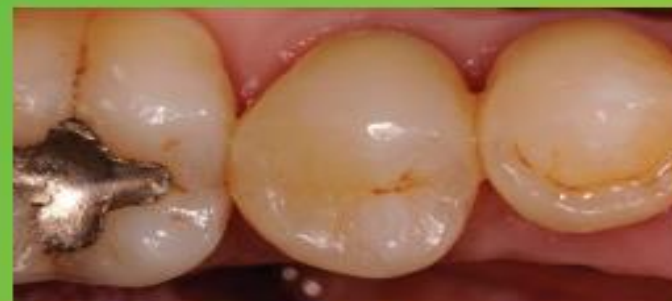

Fig. 9: Final restoration is very natural-looking and esthetic.

The 3M Difference:

In deep and tight cavities, incremental layering can be a timely challenge and lead to poor marginal adaptation. With its easy handling and excellent adaptation, 3M™ Filtek™ One Bulk Fill Restorative enables one-step placement up to 5 mm, without compromising the esthetics of posterior restorations.